



Sfogliano L, DDS¹, El-Kenaway I, DDS¹, Fraser A, DMD¹, Zhang B, DMD¹, Christoph Moschik, DDS¹, Dominguez-Mompell R, DDS¹, Moon Won, DMD¹

¹Division of Growth and Development, Section of Orthodontics, School of Dentistry, Center for Health Science, University of California, Room 63-082 CHS, 10833 Le Conte Avenue, Box 951668, Los Angeles, CA 90095-1668 USA

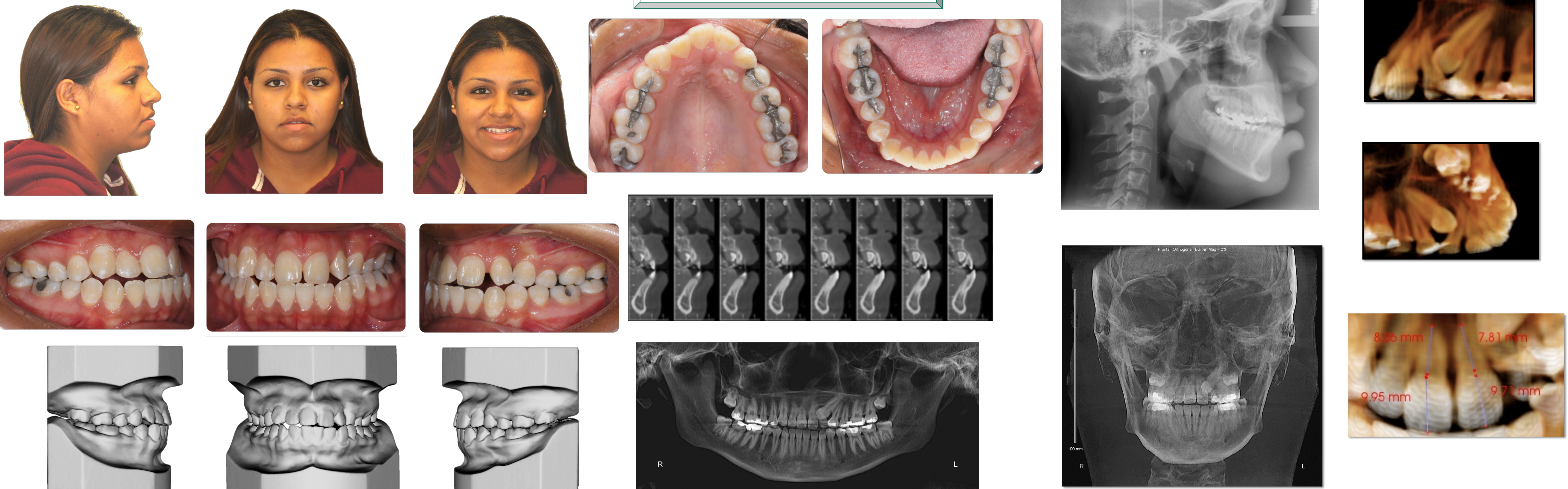
Introduction

A 15y10m female presented to the UCLA Orthodontics Clinic with the chief complaint: "I have a tooth that has not come out". Patient medical history was non contributory and she regularly visited her general dentist every six months for periodic dental exam and cleaning. Temporomandibular joint presented regular range of motions without clicking or crepitus.

Diagnosis

The patient presented with a flat profile indicative of a class III skeletal pattern. After screening and evaluation of initial records, the patient was diagnosed with a maxillary transverse deficiency and a class I skeletal relationship despite her facial appearance. The patient was dentally class III with a unilateral lingual crossbite, an impacted #11, and short roots of her upper central incisors. The overbite and an overjet were both 0 mm and there was 8 mm of crowding in the upper arch with 2mm of crowding in the lower arch.

Initial Records



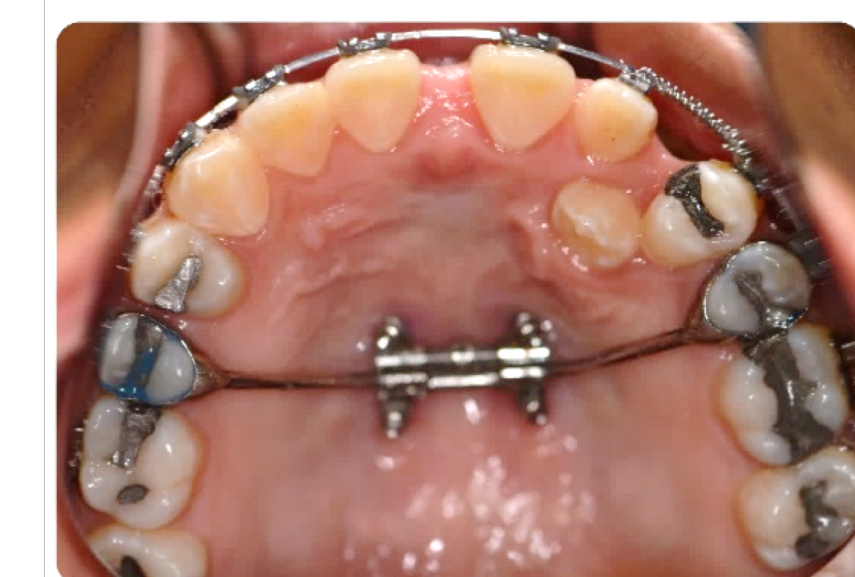Aims of treatment

Initial treatment objectives set out at the beginning of treatment included achieving ideal overbite, overjet, class I molar and canine relationships, resolving patient crowding and improving her smile esthetic. Due to her shortened roots, a non-extraction, non-surgical treatment plan was chosen using a maxillary skeletal expander (MSE) and class III elastics. With usage of skeletal anchorage via TADs, issues in all three planes were corrected and her impacted canine was successfully brought into alignment.

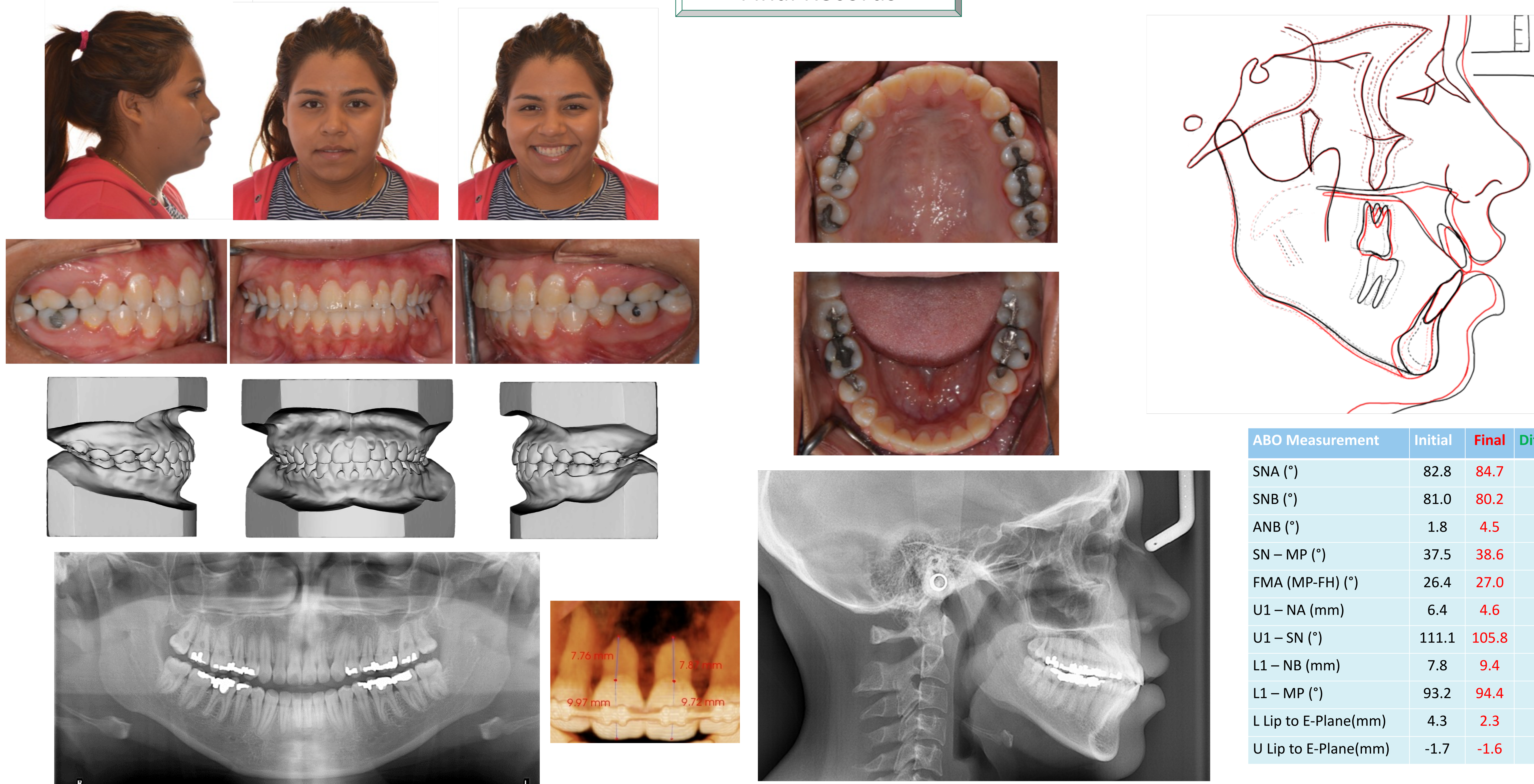
Conclusion and Discussion

This case provides insight on the potential to treat a deficient maxilla in both the transverse and anteroposterior dimensions utilizing MSE. Temporary anchorage devices (TADs) can provide an alternative to surgical treatment plans in treating transverse and A-P skeletal discrepancies. Compared to a four bi-extraction approach, the dental movement was significantly less, avoiding further problems with the blunting and resorption of the roots of the upper incisors.

Post-expansion photos



Final Records



| ABO Measurement | Initial | Final | Difference |
|----------------------|---------|-------|------------|
| SNA (°) | 82.8 | 84.7 | +1.9 |
| SNB (°) | 81.0 | 80.2 | -0.8 |
| ANB (°) | 1.8 | 4.5 | +3.7 |
| SN - MP (°) | 37.5 | 38.6 | +1.1 |
| FMA (MP-FH) (°) | 26.4 | 27.0 | +0.6 |
| U1 - NA (mm) | 6.4 | 4.6 | -1.8 |
| U1 - SN (°) | 111.1 | 105.8 | -5.3 |
| L1 - NB (mm) | 7.8 | 9.4 | +1.6 |
| L1 - MP (°) | 93.2 | 94.4 | +1.2 |
| L Lip to E-Plane(mm) | 4.3 | 2.3 | -2.0 |
| U Lip to E-Plane(mm) | -1.7 | -1.6 | +0.1 |